

# Chronic Hepatitis C Non-Responder

Eugene R. Schiff, M.D., MACP, FRCP, MACG, AGAF  
Leonard Miller Professor of Medicine  
Director, Schiff Liver Institute & Center for Liver Diseases  
University of Miami Miller School of Medicine

Prepared by:  
Ashraf Almashhrawi, MD  
Hepatology fellow  
University of Miami Miller School of Medicine

# Diagnosis

- ◆ A 55 year old white male
- ◆ First diagnosis with HCV in 1995 during a routine insurance physical with mild elevated ALT
- ◆ Genotype was 1b
- ◆ Liver biopsy in 1995 → mild to moderate fibrosis
- ◆ July 2004 → Biopsy confirmed stage 4 liver disease

# Treatment 1 (5/30/96)

- ◆ Phase III study, Interferon IM Injections (3 times weekly) + Ribavirin (1000 mg)
- ◆ Duration 24 weeks
- ◆ Non-Responder

# Treatment 2 (3/13/02)

- ◆ PEG/IFN 2a 180 U/week + Ribavirin  
(1000mg)
- ◆ 24 weeks
- ◆ Non-responder

# Treatment 3 (10/1/04)

- ◆ PEG/IFN 2b 100 U/week + Ribavirin  
(1000 mg)
- ◆ 12 weeks
- ◆ Non-Responder

# Treatment 4 (12/3/04)

- ◆ PEG/IFN 2b 50 U/week maintenance treatment
- ◆ 8 months

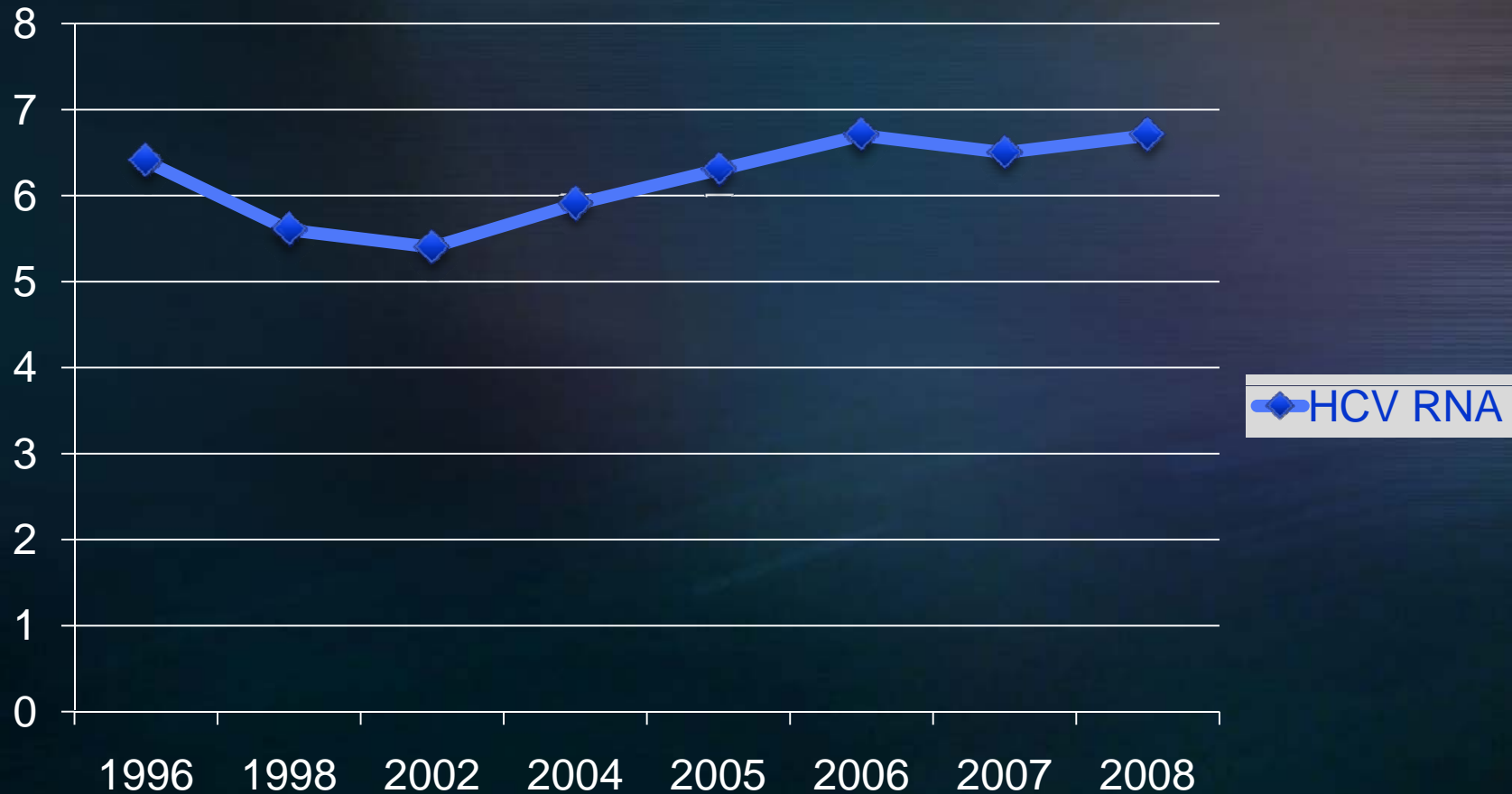
# Treatment 5 (Jan 13-April 21, 2006)

- ◆ Infergen 15 mg (daily) + Ribavirin (600 mg)
- ◆ Non-Responder

# Serial HCV RNA Levels

May 1996 through Feb 2008

At no time was HCV RNA undetectable





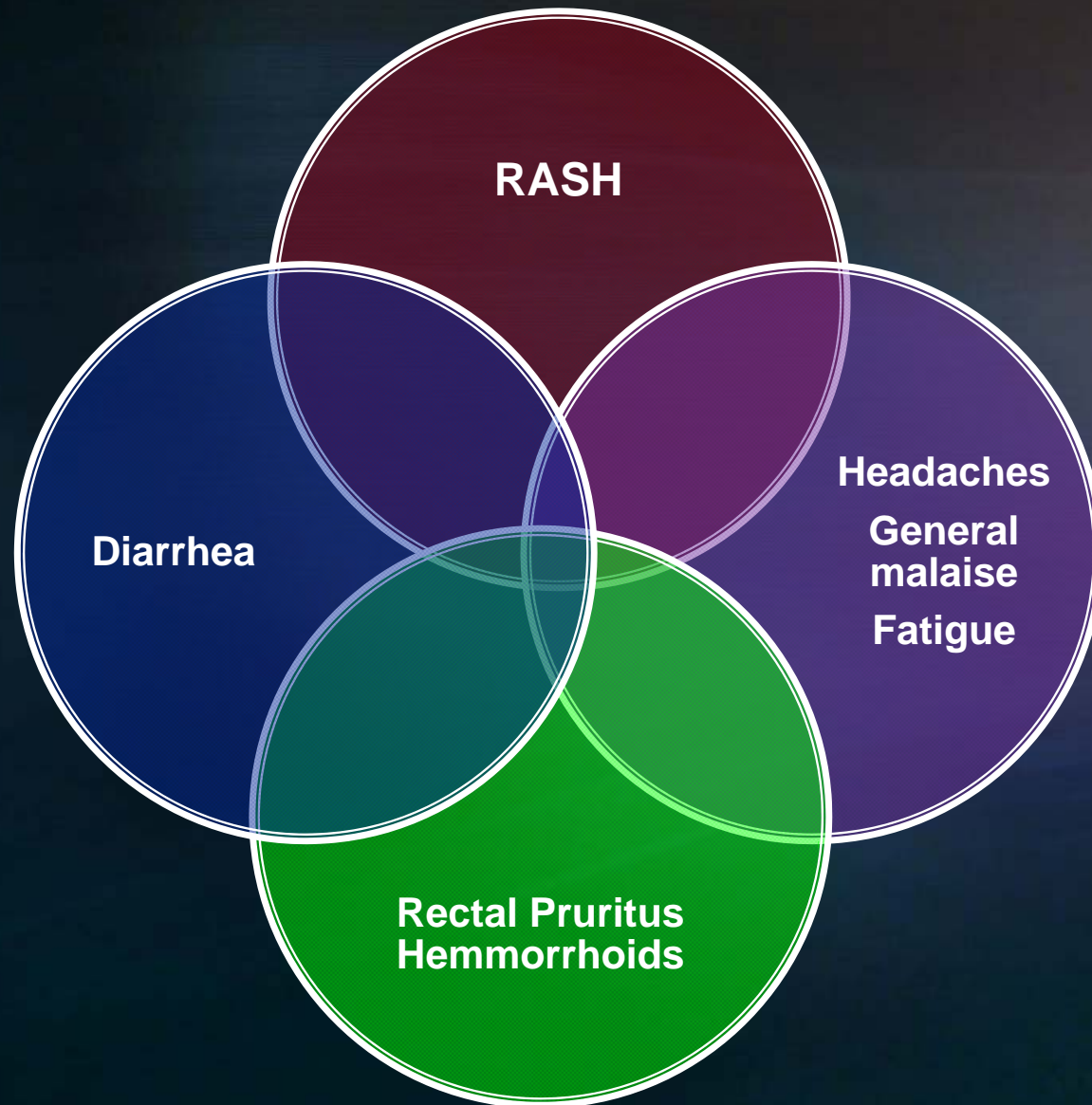
# Treatment 6 (Feb 10-July 25,2009 )

- ◆ Phase III, Double Blinded Study with  
Protease Inhibitor/PEG/IFN 2a 180 U/week  
+ Ribavirin
- ◆ 24 weeks
- ◆ Non-Responder
- ◆ Received placebo

# Treatment 7 (August 2010-now)

- ◆ Phase III Rollover Study with Protease Inhibitor/PEG/IFN 2a 180 U/week + Ribavirin
- ◆ Ongoing
- ◆ HCV RNA <25 at week 4
- ◆ HCV RNA = 0 at week 8
- ◆ HCV RNA = 0 at week 12

# Adverse reactions



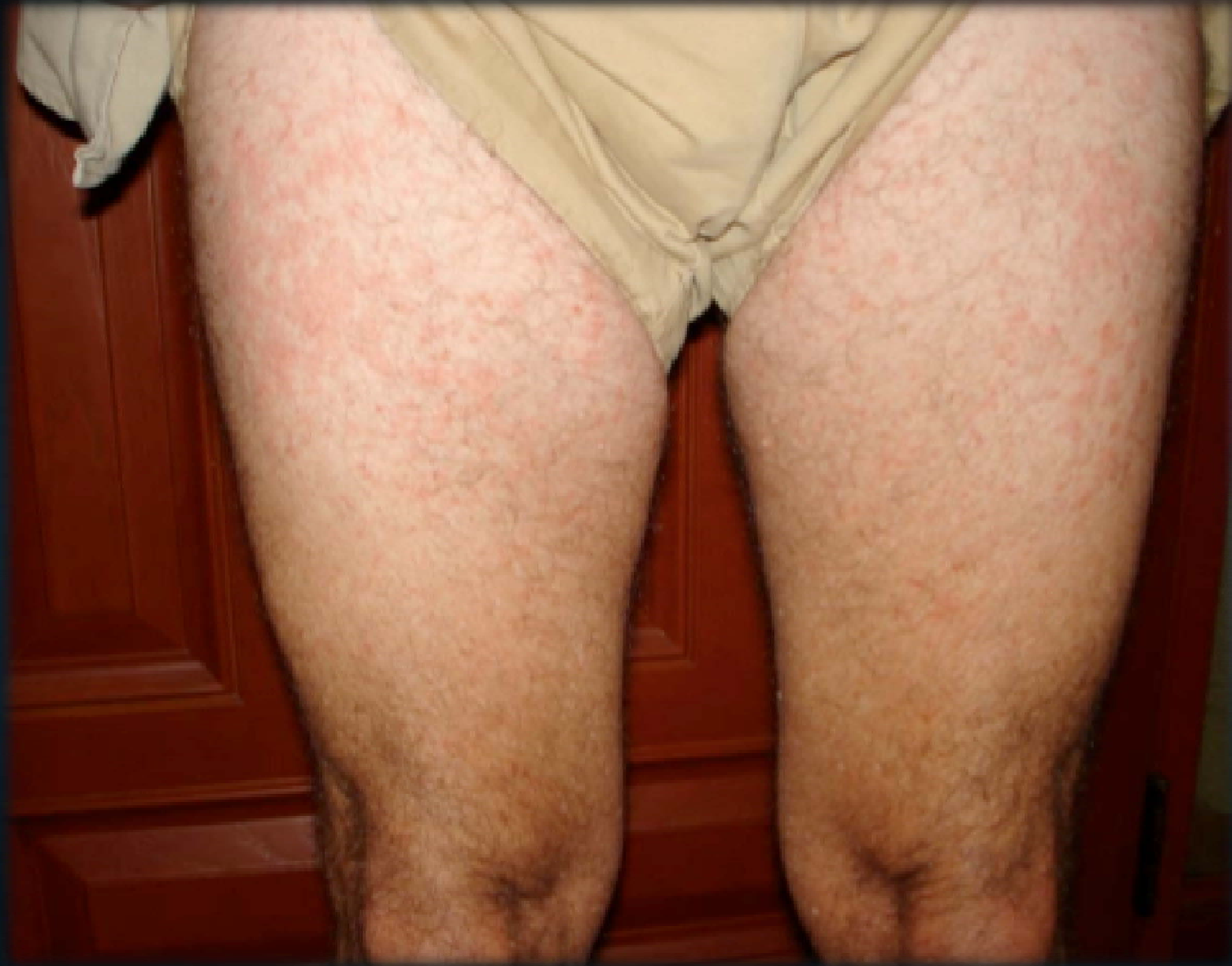# Rash

**Day 4** Rash on chest and upper legs

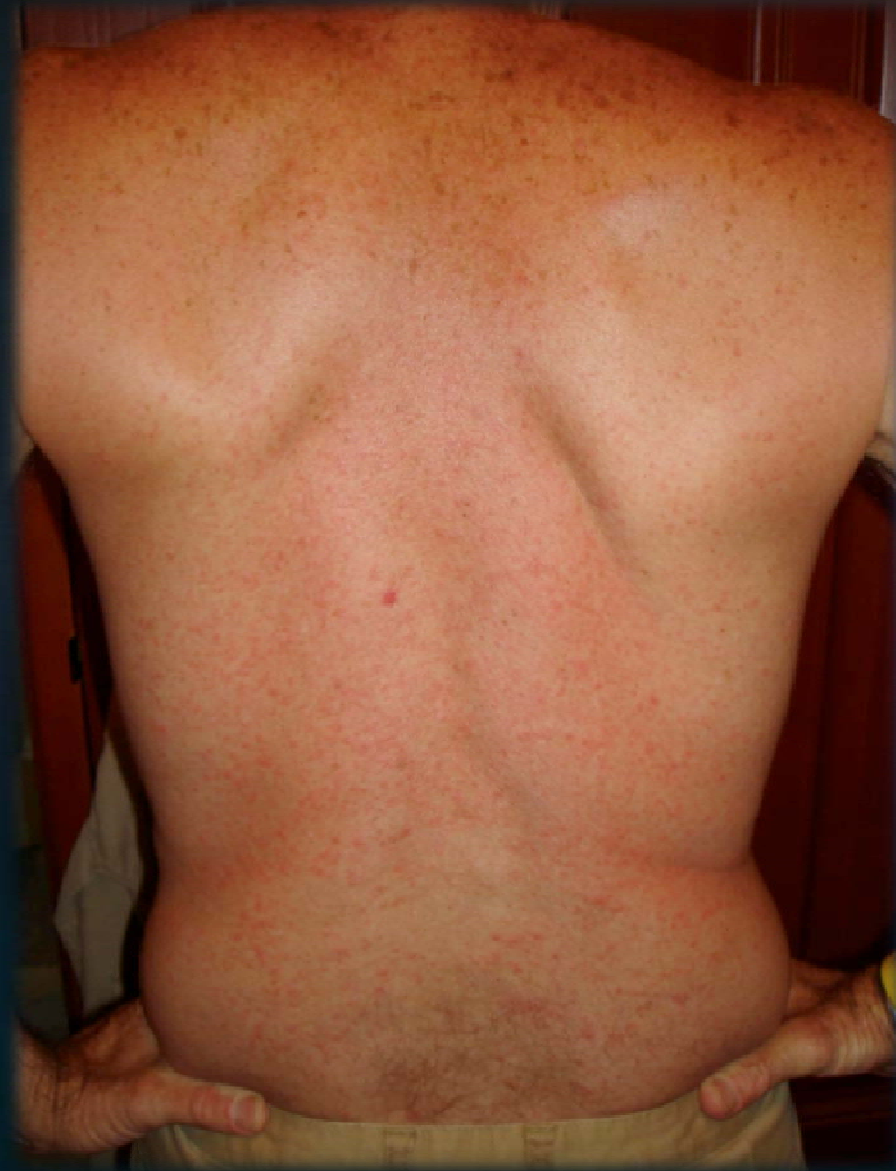**Days (6, 7)** Diffuse with moderate to severe irritation

- Topical steroidal ointment
- Benadryl
- Aveno bath
- Aquaphor ointment
- Tylenol Extra Strength
- Ambien

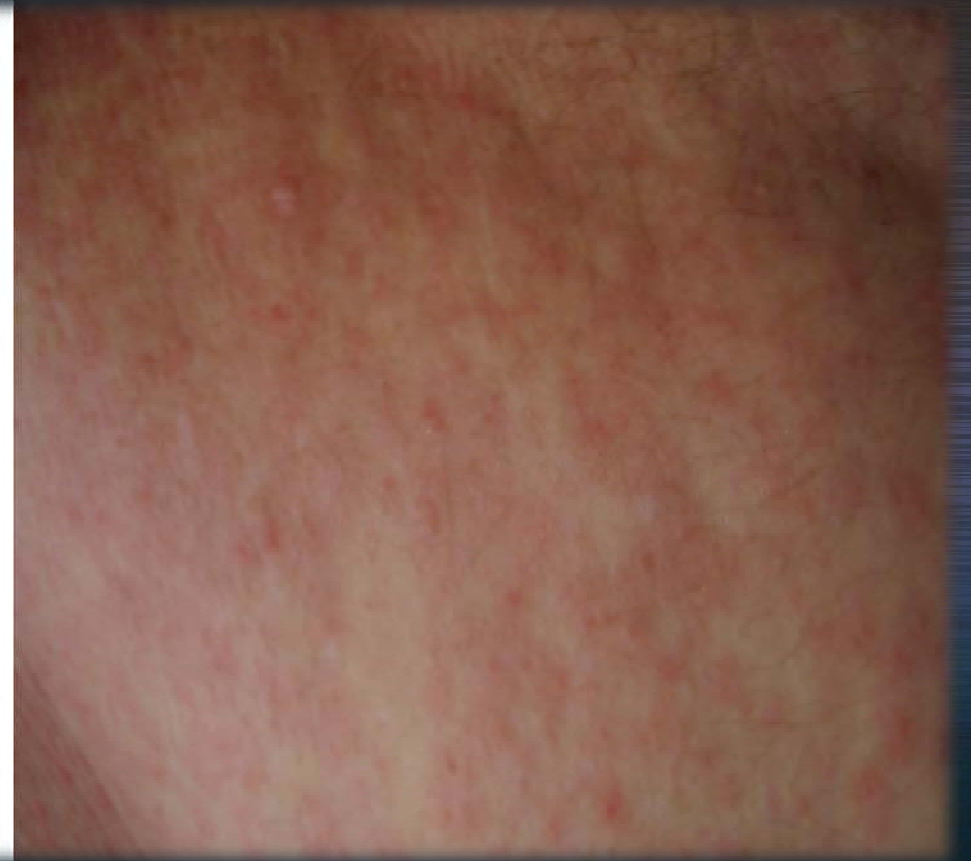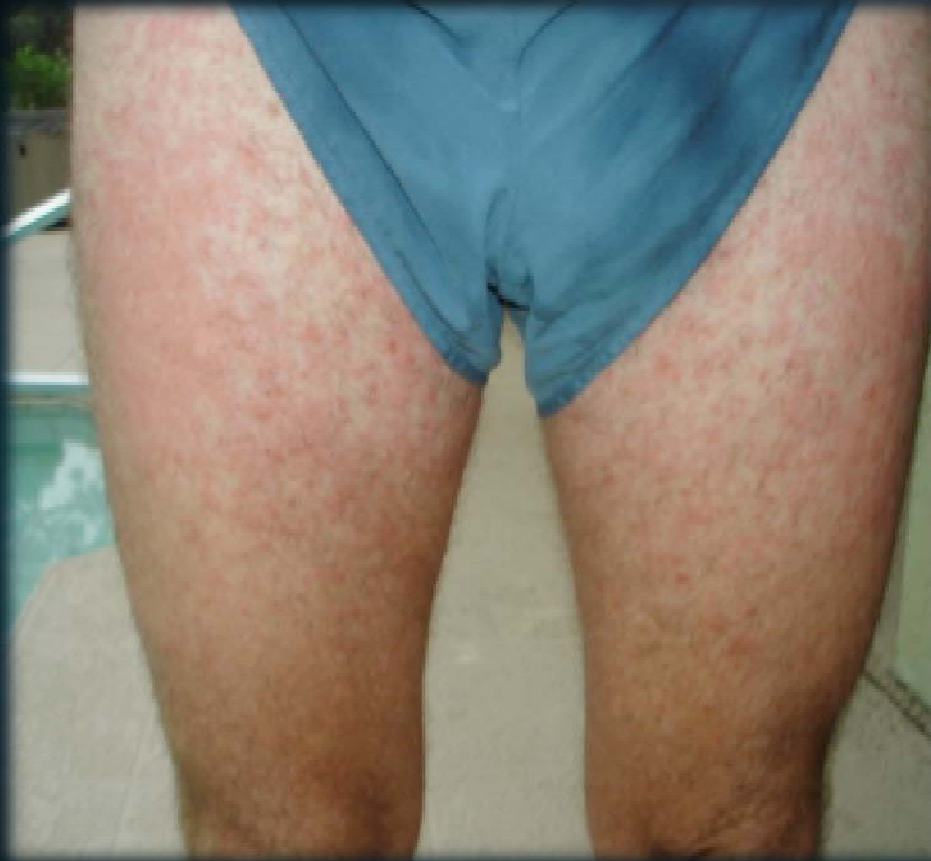Day 5



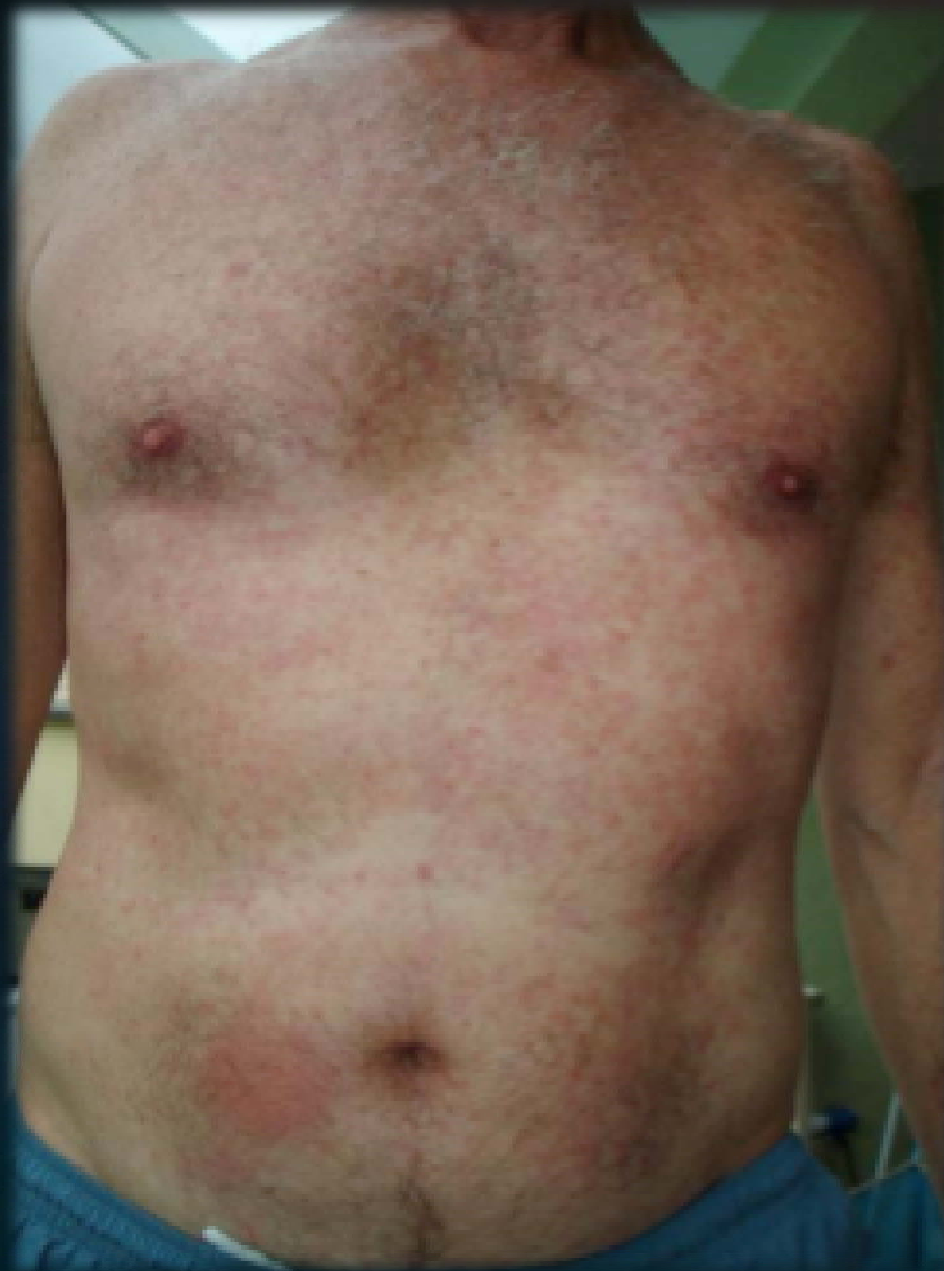**Day 5**



Day 6



**Day 6**





# Rash

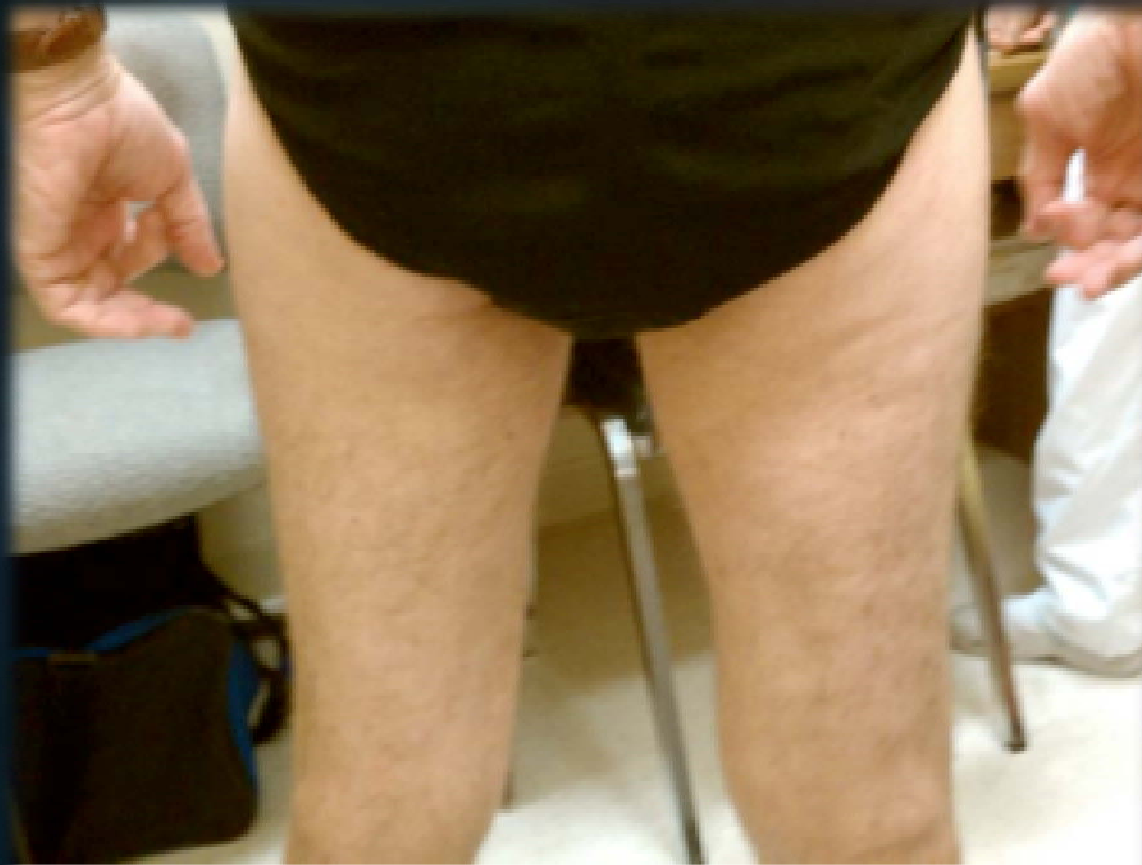**Day 8** Rash subsided on back dramatically and became less on chest.

**Day 9** Rash continued to subside

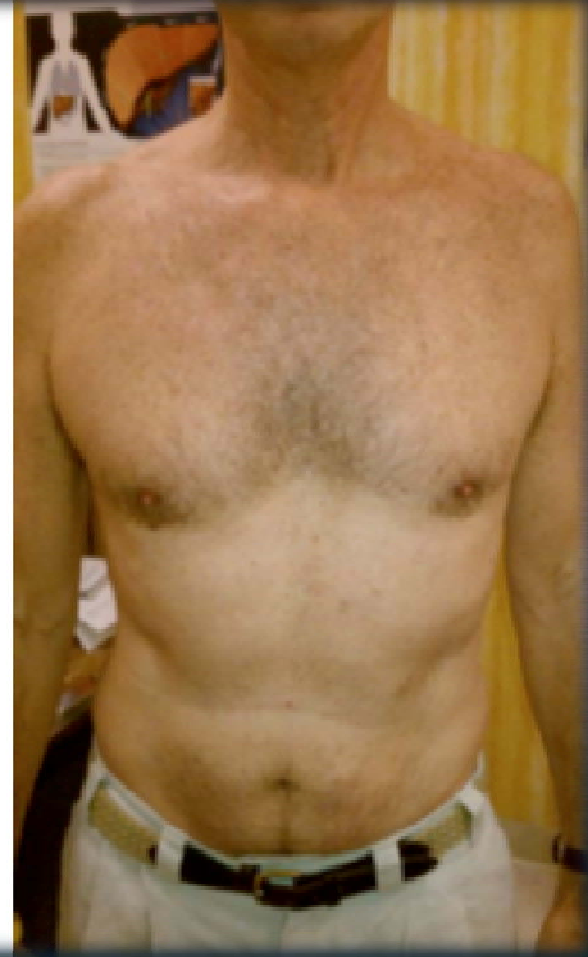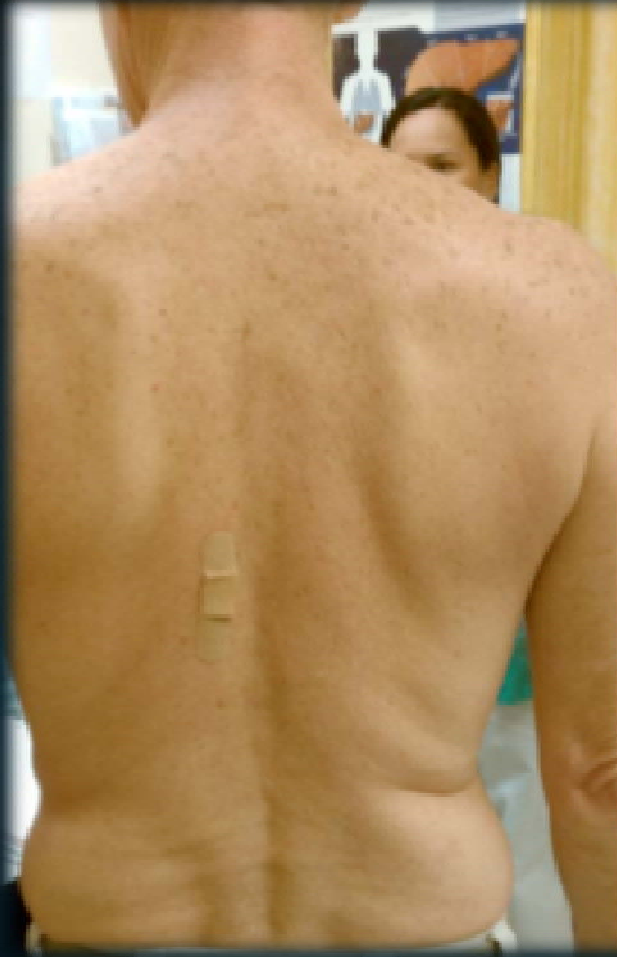**Day 10** Rash was only present on upper thighs

**Week 4** Rash almost resolved

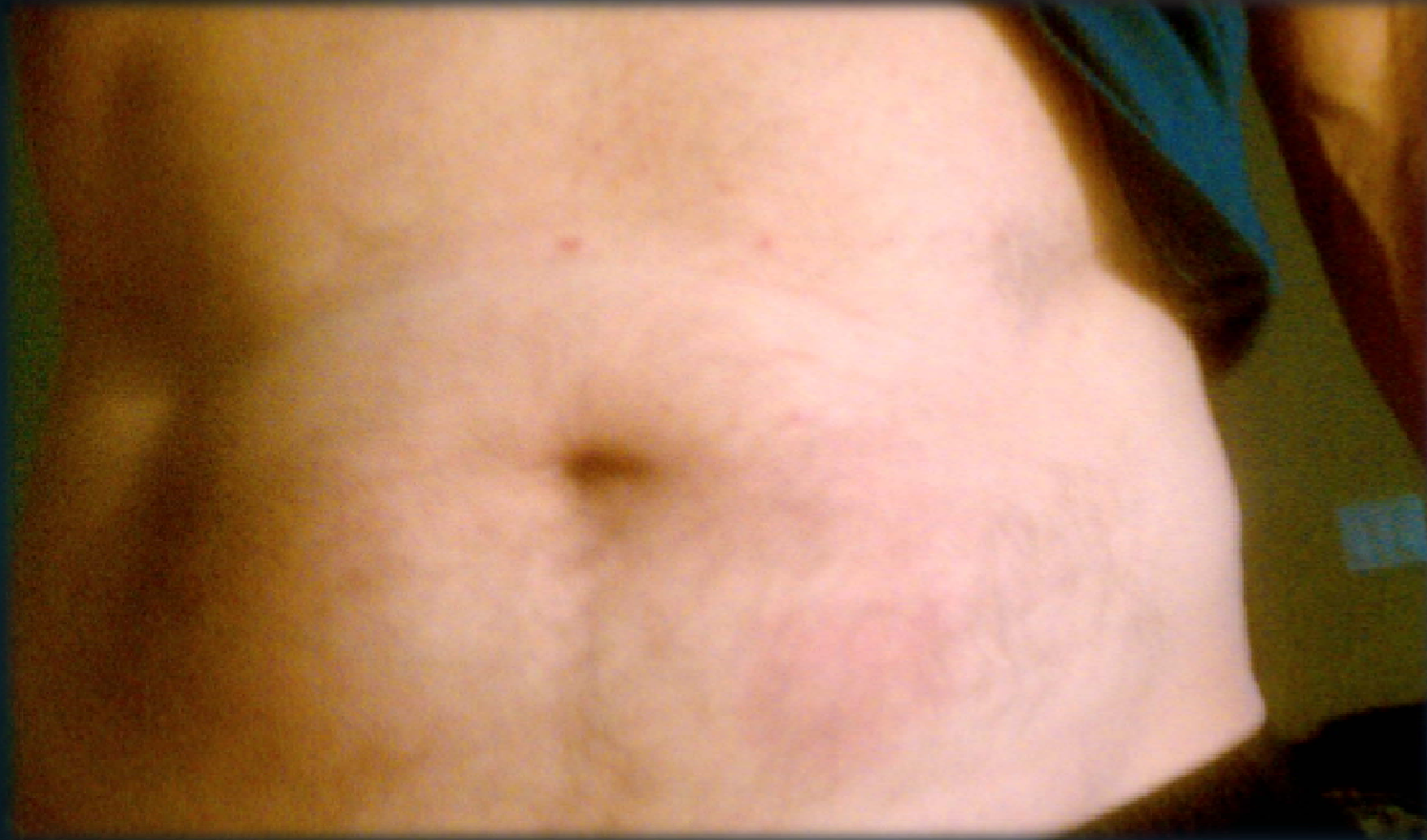## Week 4



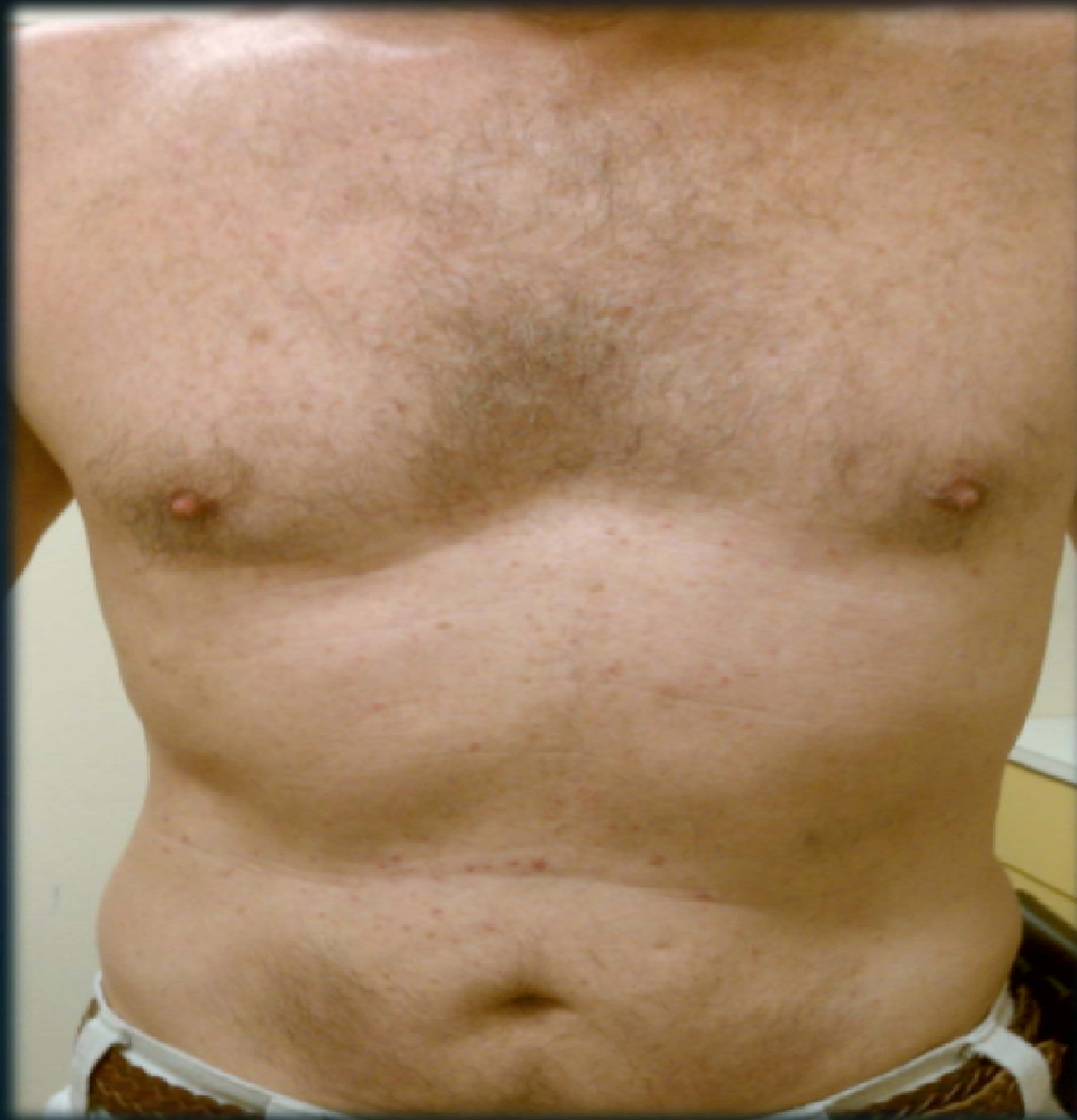# Week 4



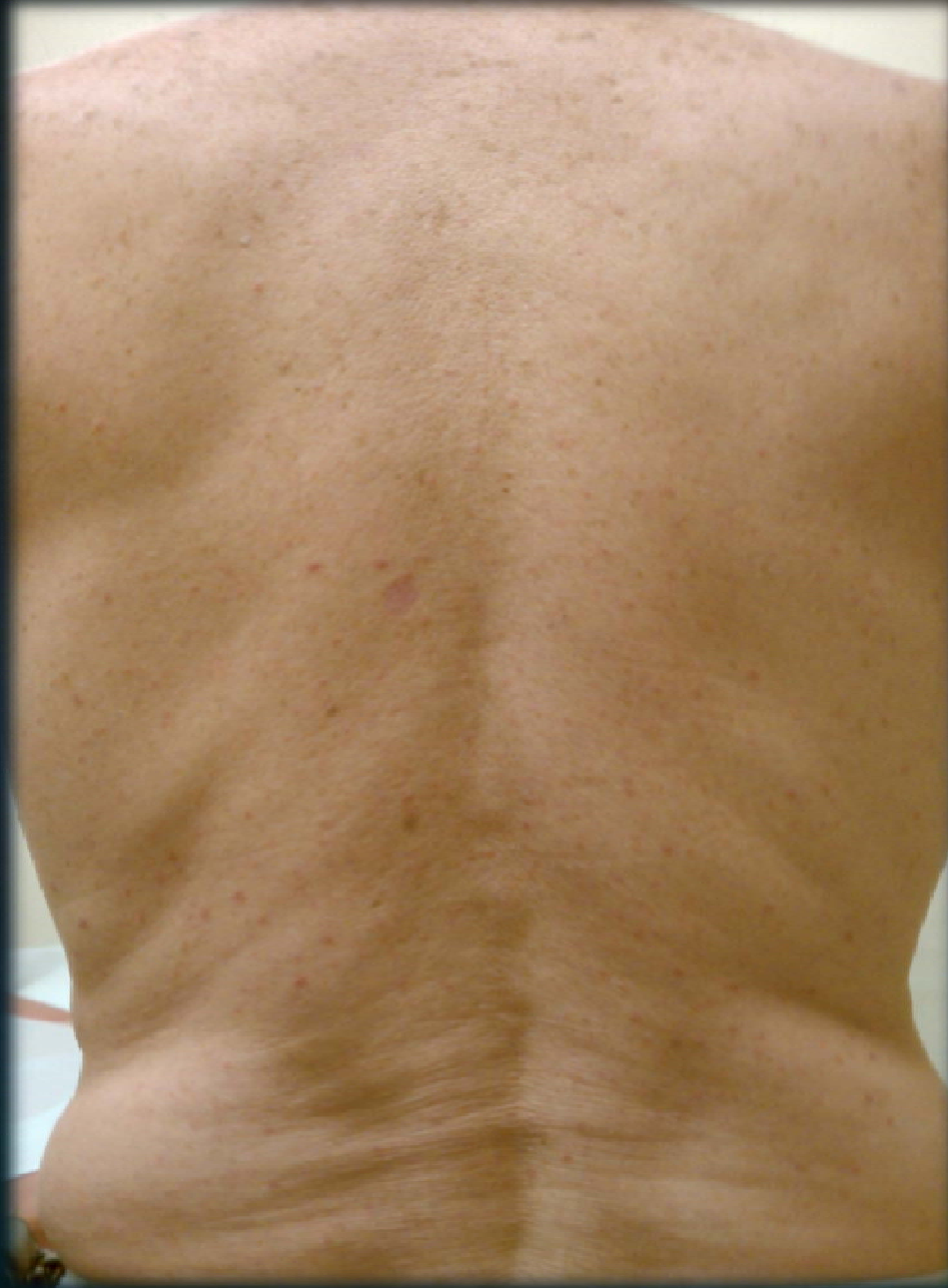**Week 4**



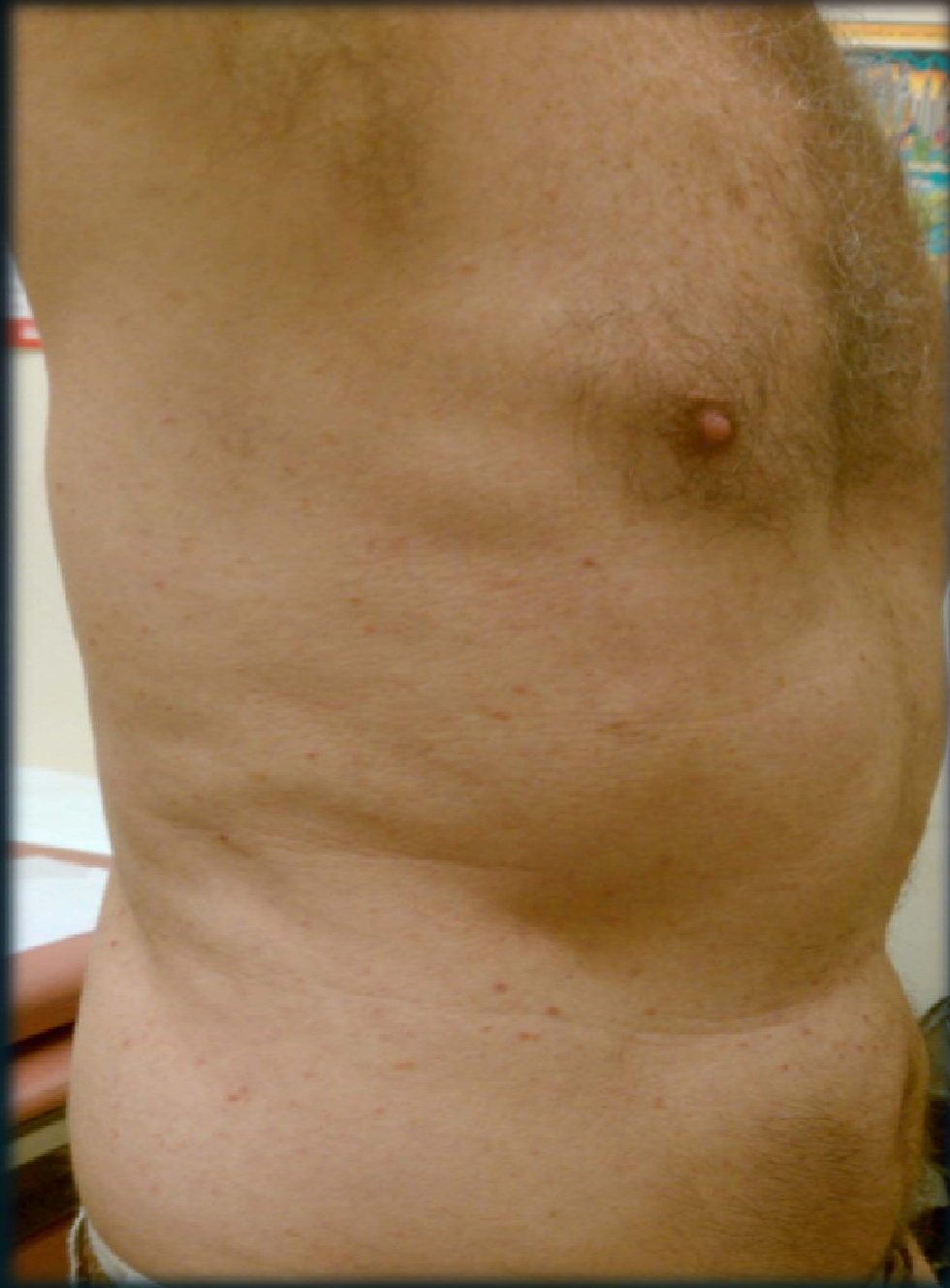**Week 12**



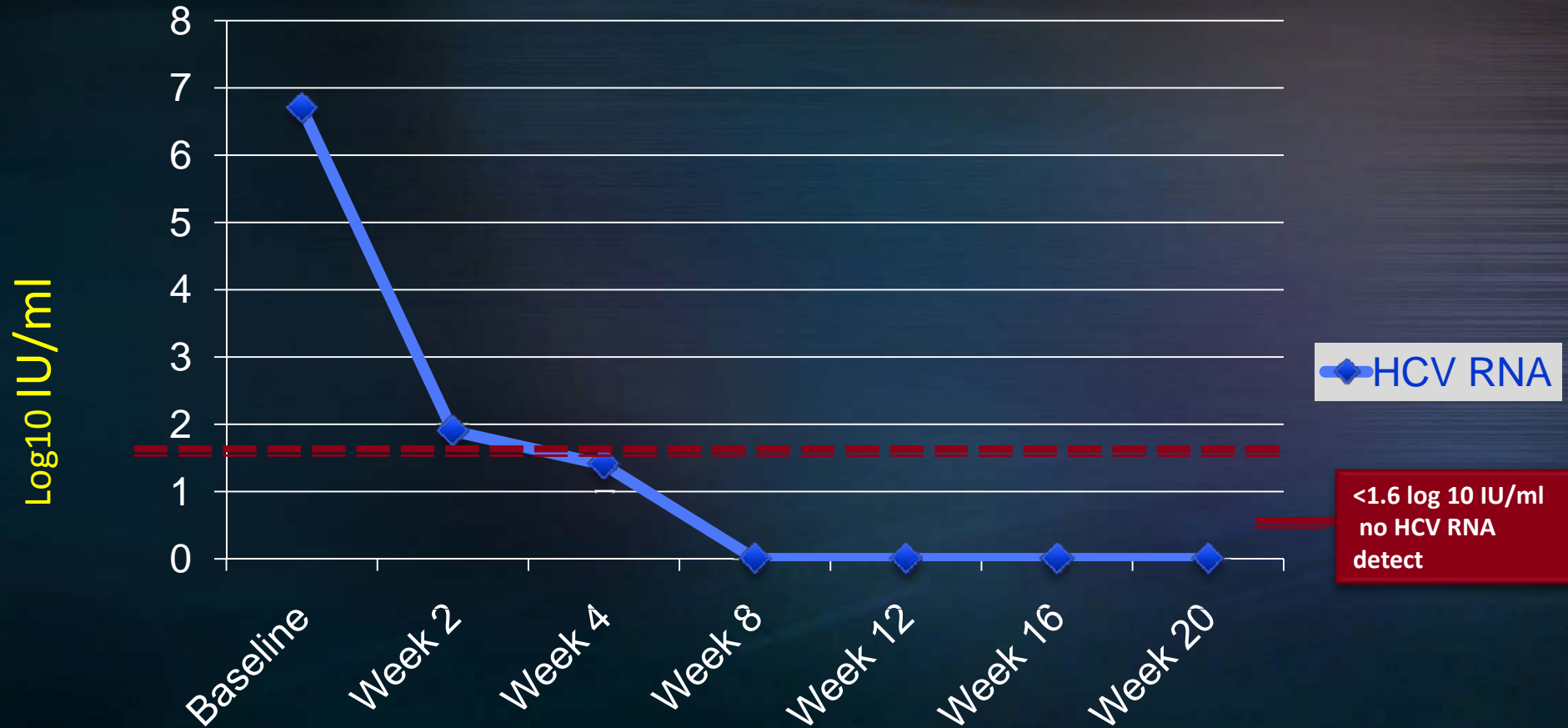
**Week 12**



**Week 12**



# TPR + PR 24 Weeks





# IL28B Polymorphism Genotype

- ◆ TT genotype