

# 4<sup>th</sup> Paris Hepatitis Conference



## Case report

**Pierre A. Clavien, MD, PhD**

Department of Surgery  
University Hospital Zurich  
Zurich, Switzerland



University of  
Zurich<sup>UZH</sup>

# 1st Case

# OLT for HCC

48 year old male

Liver cirrhosis CHILD A

Hepatitis B: known since 15 years (1993)

HBs antigen carrier without replication

**NO** treatment (only lamivudine available)

Co-morbidities: MI February 2002

**Kidney transplantation** July 2004

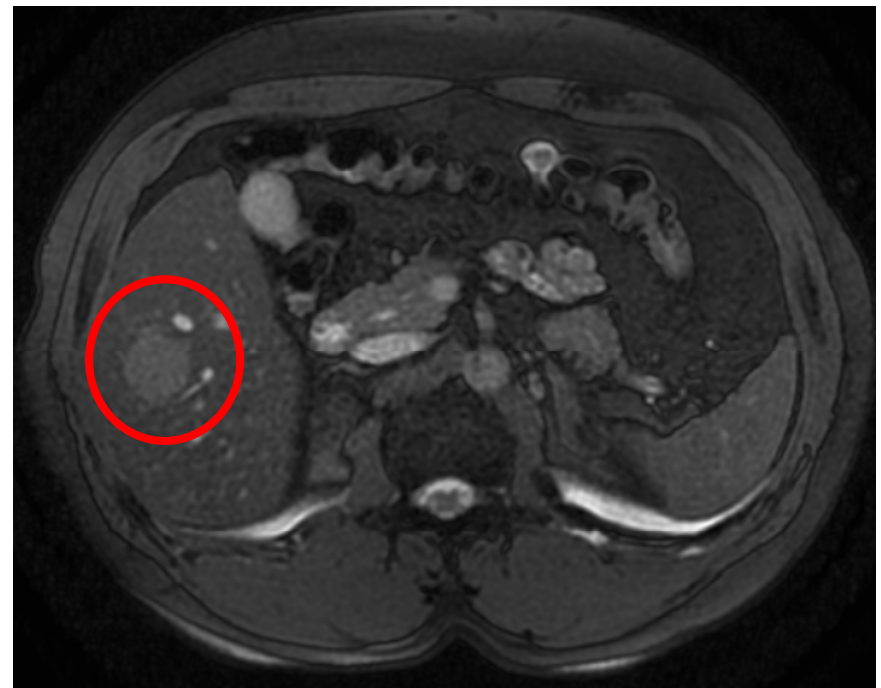
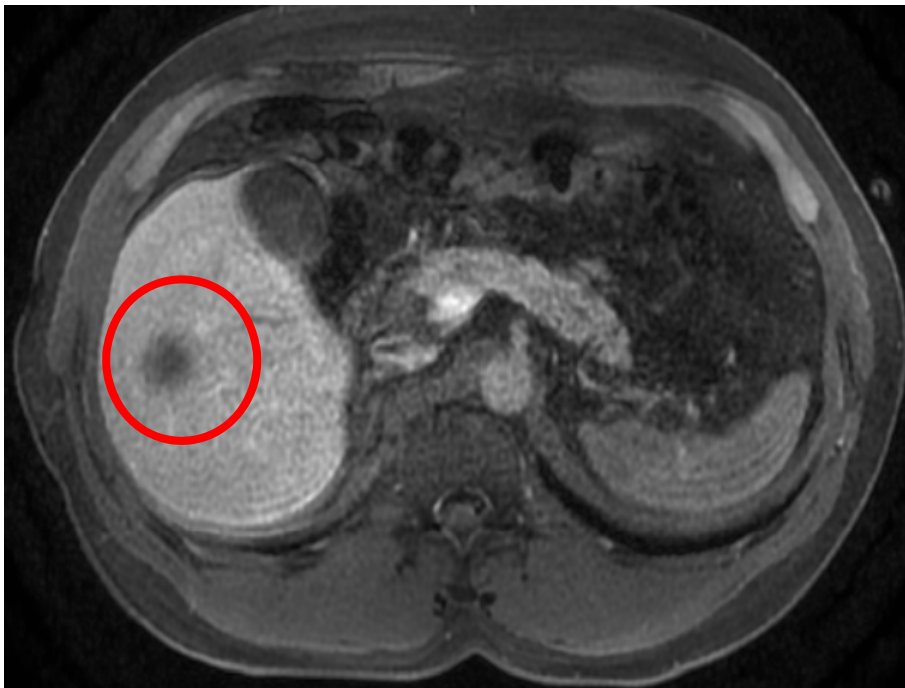


# 1<sup>st</sup> Case

# OLT for HCC

June 2007:

- Increased Virus load > 30.000 IU
- HCC suspected tumor segment V/VI; 2.7 cm
- AFP 1.8  $\mu\text{g/l}$



# 1<sup>st</sup> Case

# OLT for HCC

## Bridging Therapy

June 2007: Start with Telbivudine (Sebivo) Therapy

Dosage: 600 mg daily

-- Virus not detectable

July 2007:

**Wedge resection  
segment V/VI**

*Histopathology:*

HCC of 2.6 cm

No microvascular invasion



# 1<sup>st</sup> Case

# OLT for HCC

Patient at risk for tumor development:

- chronic Hepatitis B
- under immunosuppression after kidney transplantation
- familial disposition (brother also HCC)

Decision December 2007:

**Listing Patient for Liver Transplantation**

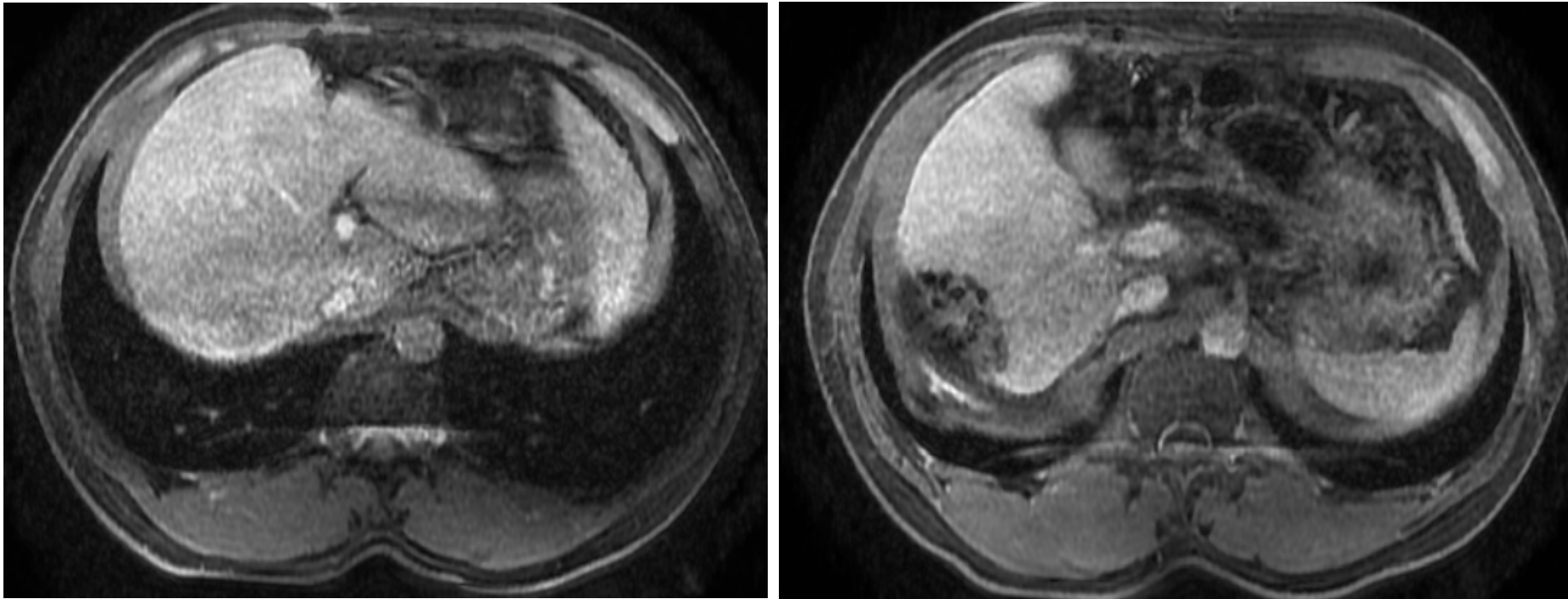


# 1<sup>st</sup> Case

# OLT for HCC

MRI - before transplant

**NO suspected HCC recurrence**



# 1<sup>st</sup> Case

# OLT for HCC

June 2008:

**OLT**

Histopathology:

**No tumor**

Hepatitis B treatment post transplant:

Hepatect - Dosage: 10.000 IE / 12 weeks + Telbivudine

HBV DNA negative

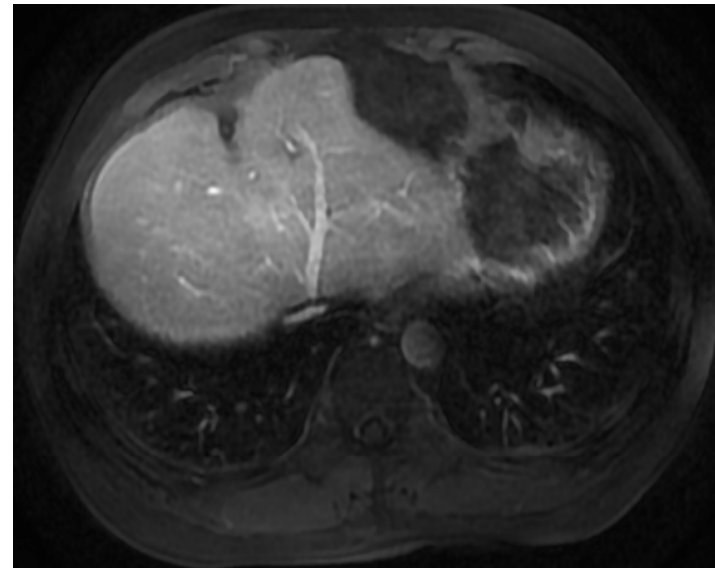
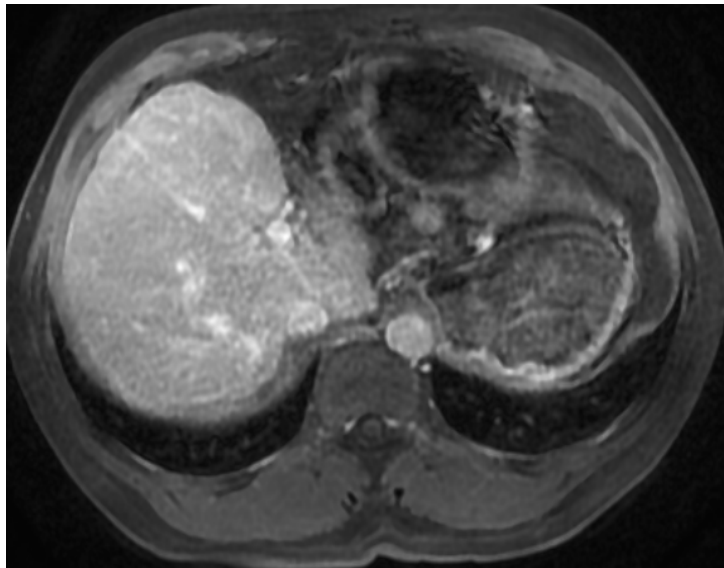


# 1<sup>st</sup> Case

# OLT for HCC

Last follow up:

January 2011



52 year old male in good general conditions

**NO** Hep B and HCC recurrence 2.5 years after OLT



# 2<sup>nd</sup> Case

# OLT for HCC

42 year old male

Liver cirrhosis CHILD A

Hepatitis B: known since 6 years

Liver biopsy 2 years ago: mild active Hepatitis B with portal fibrosis and coinfection with Hepatitis D

Therapy: alpha Interferon 3x9 Mio units s.c.

Interruption of treatment after 2 weeks due to severe side effects



# 2<sup>nd</sup> Case

# OLT for HCC

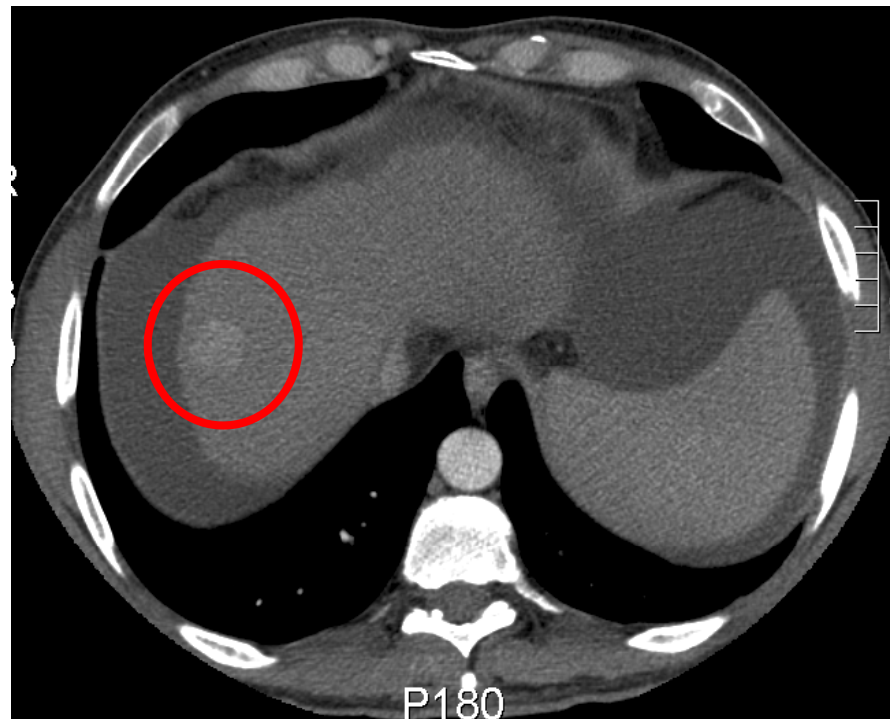
July 2007:

- Liver cirrhosis CHILD B, 8 Points
- uncorrected MELD Score 13

suspicion of HCC Segment VII

AFP 112.4  $\mu\text{g/l}$

CT  
arterial phase



# 2<sup>nd</sup> Case

# OLT for HCC

## Bridging Therapy

August 2007:

**TACE**

with Doxorubicin

Listing patient for liver transplantation

Looking for potential living donor



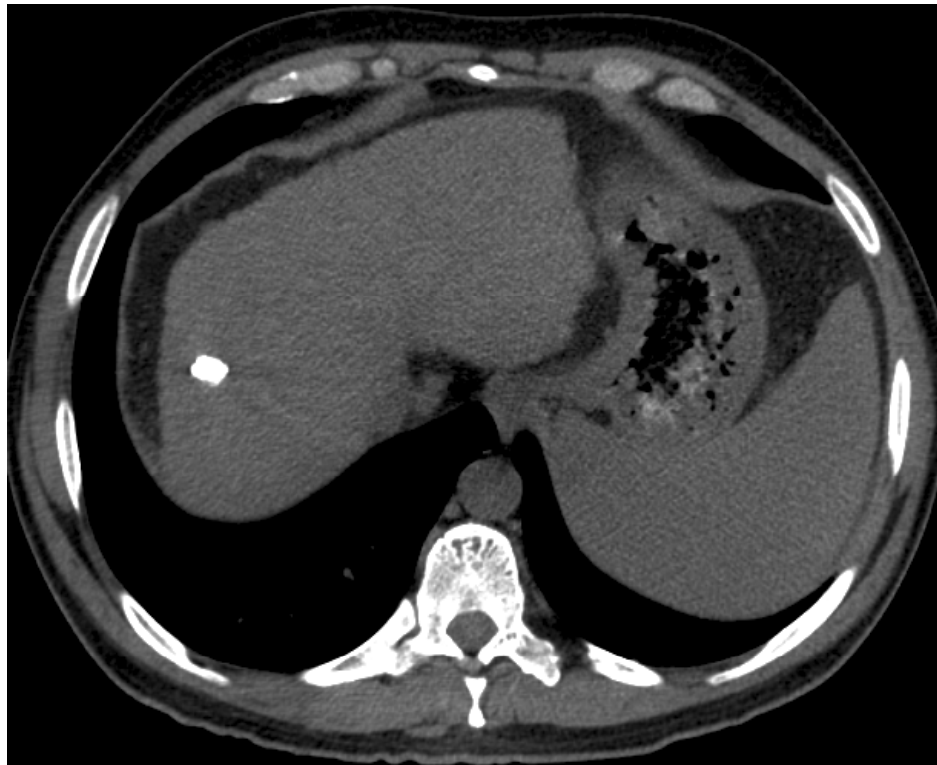# 2<sup>nd</sup> Case

# OLT for HCC

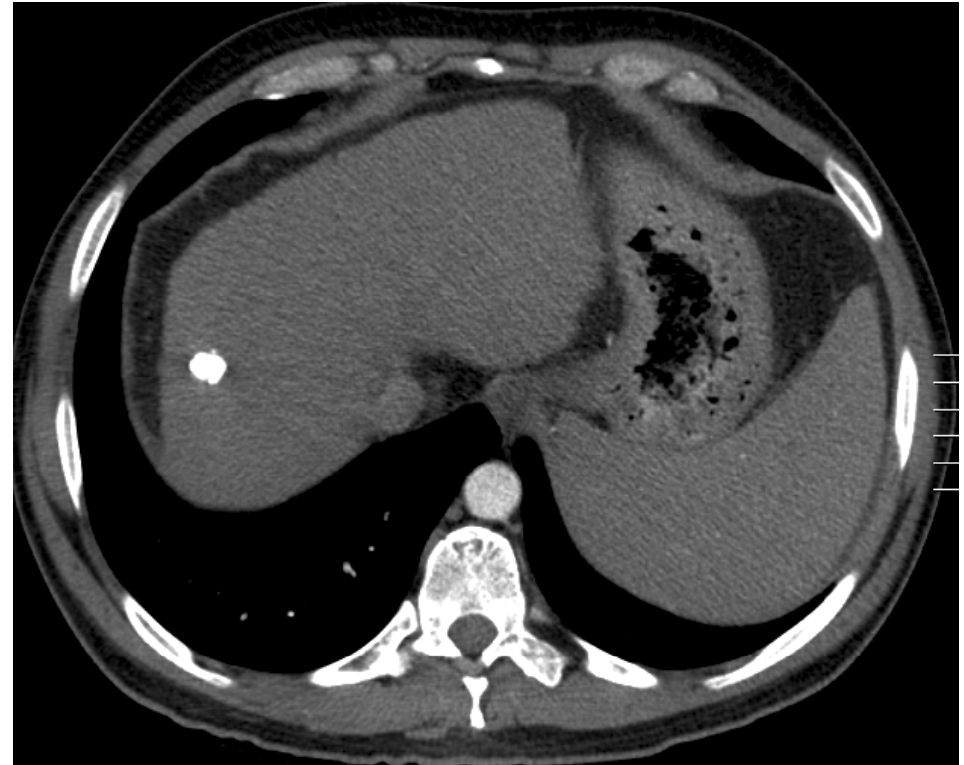CT scan - 8 weeks after the intervention

**complete embolisation**

native phase



arterial phase



# 2<sup>nd</sup> Case

# OLT for HCC

January 2008:

## Living donor liver transplantation

Right liver lobe; 3 veins

*Histopathology of the explanted liver:*

Nodule of 1.2 cm - completely necrotic

No microvascular invasion

# 2<sup>nd</sup> Case

# OLT for HCC

Last follow up:

December 2010

45 year old male in good general conditions

NO Hepc B and HCC recurrence 3 years after LDLT

*Hepatitis B Treatment post transplant:*

Hepatect 10.000 IE/12 weeks +

Lamivudine





Thank you



University of  
Zurich<sup>UZH</sup>

# 1<sup>st</sup> Case

# OLT for HCC

69 year old male, 81 kg

Liver cirrhosis CHILD A

Hepatitis C: known since 5 years

treated by Peginterferon and Ribavirin  
(responder)

**2005 Sept. AFP 313  $\mu\text{g/l}$**

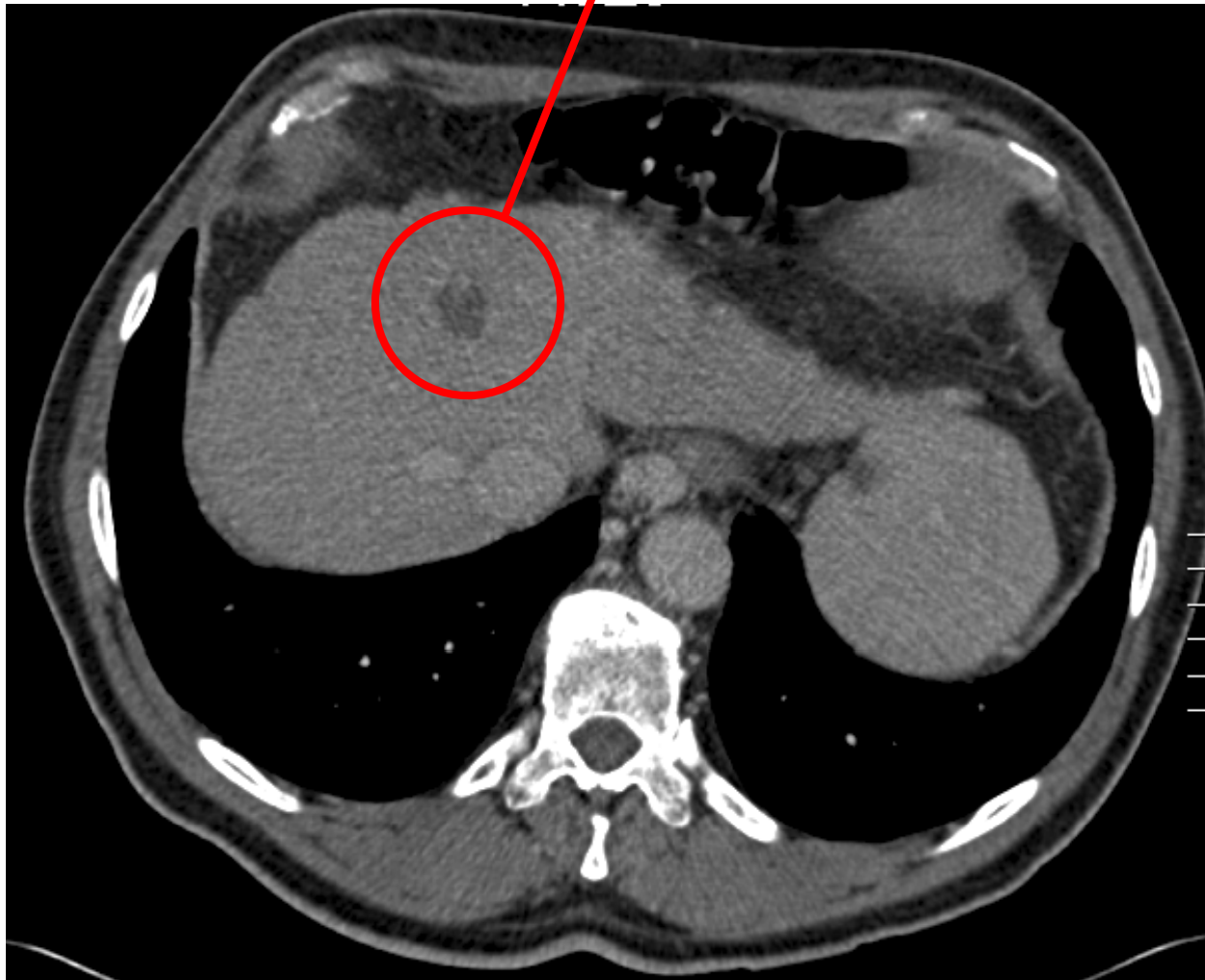


# 1<sup>st</sup> Case

# OLT for HCC

CT scan ~~arterial~~ phase

Liver segment IVa  
inhomogen, hypodense lesion of 1.7 cm



# 1<sup>st</sup> Case

# OLT for HCC

## Bridging Therapy

January 2006

**TACE**

with Doxorubicin

Liver Segment IV

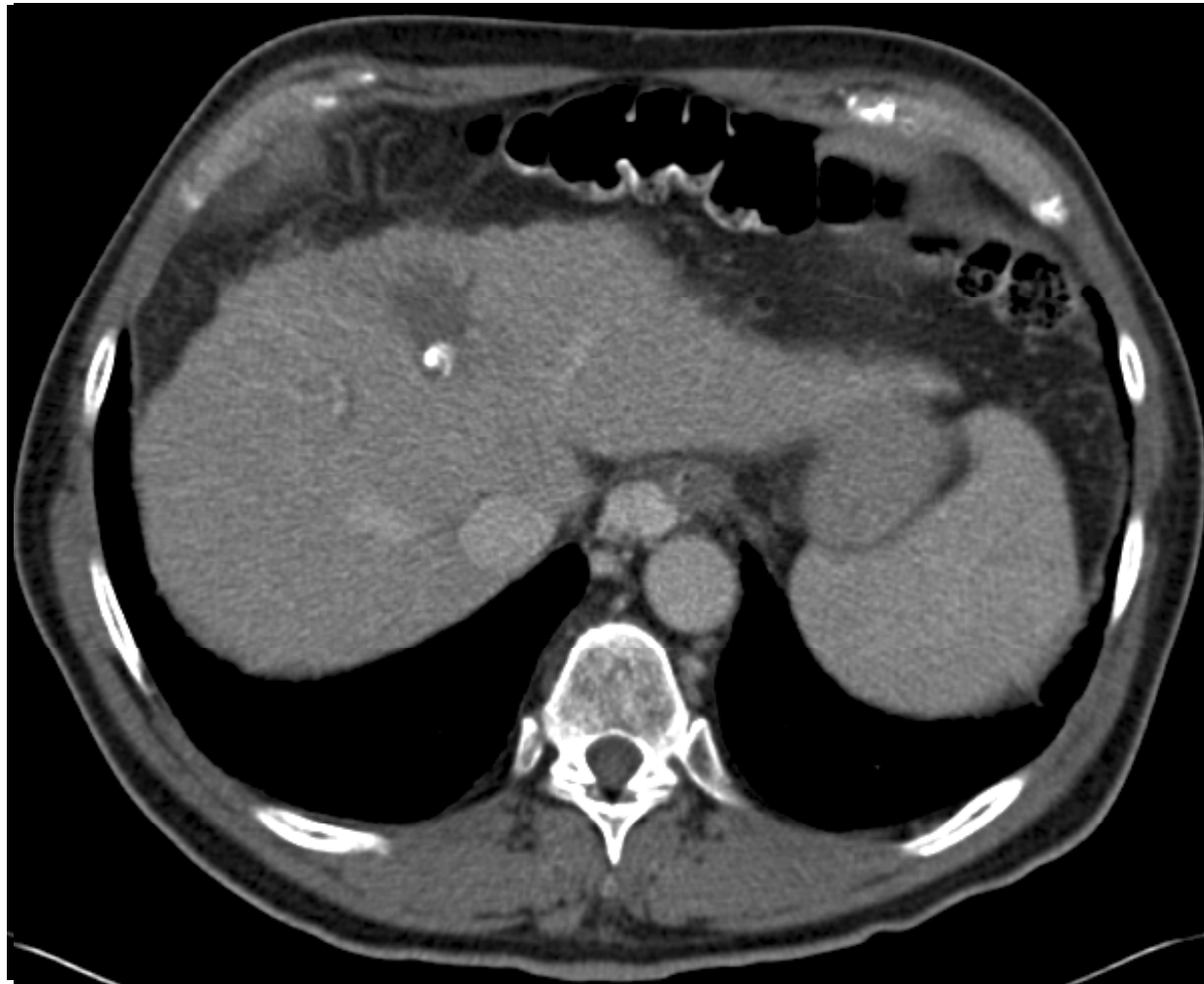
Patient included into a study, therefore  
February 2006

**RFA**

# 1<sup>st</sup> Case

# OLT for HCC

CT scan - 8 weeks after the intervention



# 1<sup>st</sup> Case

# OLT for HCC

February 2006

Listing patient for liver transplantation

October 2006

**OLT**

Histopathology of the explanted liver:

Nodule of 2.3cm - completely necrotic

No microvascular invasion

Postoperative uneventful course

Length of hospital stay: 13 days

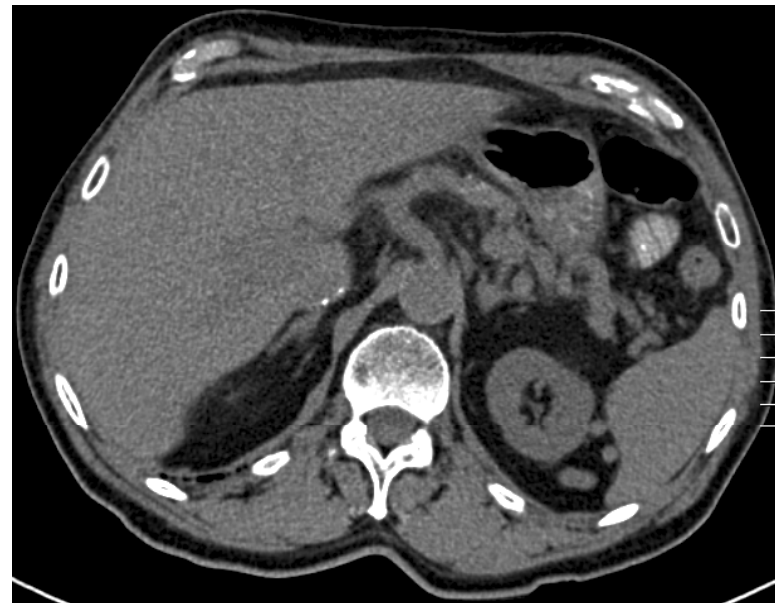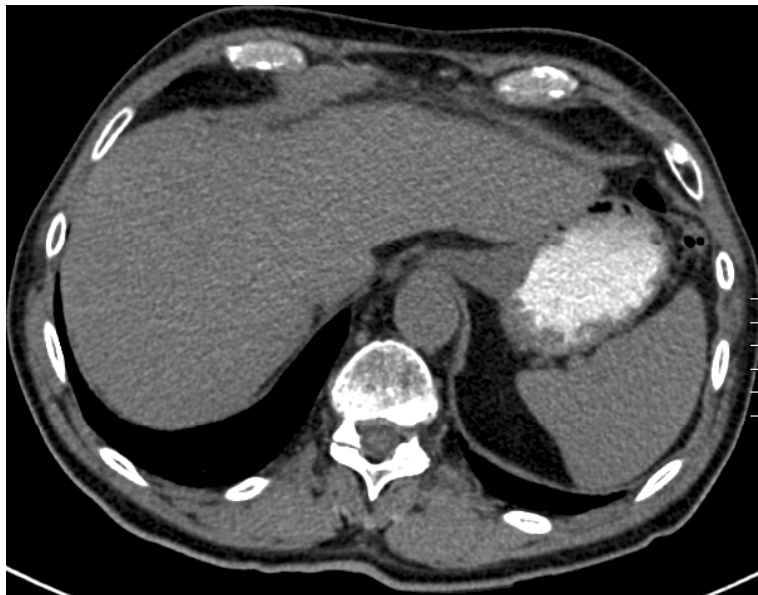# 1<sup>st</sup> Case

# OLT for HCC

Last follow up: November 2010

69 year old male in good general conditions

**NO** Hep C and HCC recurrence 4 years after OLT



## 2<sup>nd</sup> Case

## OLT for HCC

46 year old female, kg

Liver cirrhosis CHILD A

Hepatitis C: known since 11 years due to transfusion after cesarean; **NO** medical treatment

**2000 Nov. 1st decompensation  
spontaneous bacterial peritonitis**



# 2<sup>nd</sup> Case

# OLT for HCC

November 2000 - February 2002

regular ambulant follow up - liver function stable

March 2002

CHILD B: 12 points

***Decision:*** Listing patient for liver transplantation



# 2<sup>nd</sup> Case

# OLT for HCC

December 2004

Patient still on waiting list

On regular controls:

AFP > 50 yg/l 

New lesions suspicious for HCC in segment VII

January 2005

**TACE**

with Doxorubicin



Liver Segment VII - single lesion 15 mm

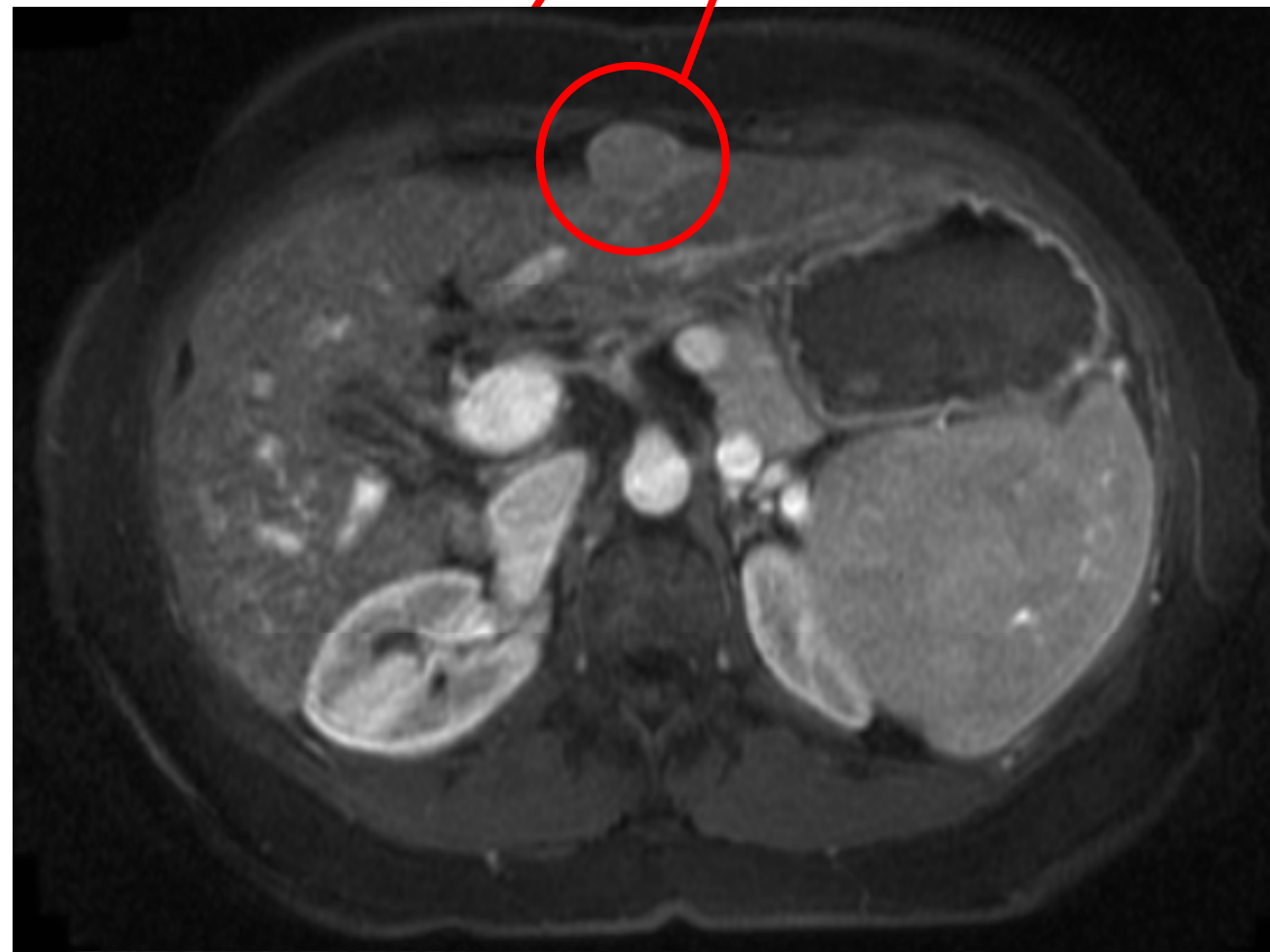

# 2nd Case

# OLT for HCC

September 2005

MRI



Liver segment VII  
Lesion suspicious for HCC on after TACE

# 2<sup>nd</sup> Case

# OLT for HCC

October 2005

**TACE**

with Doxorubicin

Liver Segment III

November 2005

**OLT**

Histopathology of the explanted liver:

Two nodules of 2.3cm and 0.8 cm – completely necrotic

No microvascular invasion

# 2<sup>nd</sup> Case

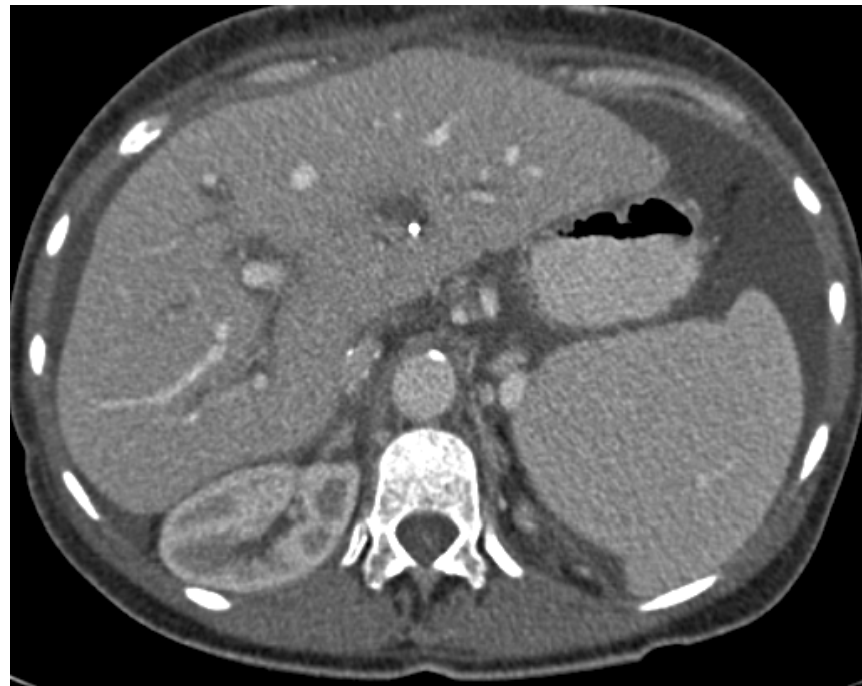# OLT for HCC

Last follow up:

October 2010

55 year old female in good general conditions

NO Hepc C and HCC recurrence 5 years after OLT



Thank you



University of  
Zurich<sup>UZH</sup>