

KE, female. born: 1956, biologist

- **1988 Sectio, blood transfusions**
- **1992 ligation of Fallopian ducts, at preoperative screening anti-HCV pos**
- **1994 referral to outpat. clinic, almost normal transaminases, no treatment**
- **1997 ALT 165**

KE, female. born: 1956, biologist

Lab. results 1/1997

- AST 77 IU/ml (normal: -15*)
- ALT 107 IU/ml(normal: -19*)
- Gamma-GT 269 IU/ml (normal: -18*)
- Alk.Phosphatase: 128 IU/ml
- pCHE: 5,39 kU/ml
- Bilirubin, coagulation, CBC: normal

* In 1997

KE, female. born: 1956, biologistogin

- **Caeruloplasmin, Ferritin: normal**
- **HCV PCR pos**
- **ANA 1:640 pos, ASMA 1:320 pos, anti ssDNA 22,5**
- **HLA: A2,24; B13,15; Cw3,w6;DR4,7**

Liver biopsy 1997

- Chronic Hepatitis (Typ C) :portal und lobular grade 2, Fibrosis grade 2 according Ludwig).

KE, female. born: 1956, biologist

- **Which treatment?**
- **1997?**
- **2015?**

KE, female. born: 1956, biologist

- **5 MU IntronA/every other day**
- **nonresponder, treatment stopped after week 12**
- **One month later, test treatment with steroids, no response**
- **No further treatment, out patient controls, mildly increased transaminases**
- **1999 ALT increased again**

Liver biopsy 1999

- Chronic hepatitis C; inflammatory activity: portal and lobular 3, fibrosis 3 according Ludwig.

KE, female. born: 1956, biologist

- **What to do now?**
- **1999?**
- **2015?**

KE, female. born: 1956, biologist

- **Repeated treatment with 25 mg Prednisolon/d, no improvement**
- **5/99-11/99: treatment with MU IntronA/ every other day +Ribavirin 800**
- **Develops hypothyreosis**
- **Nonresponder**

Liver biopsy 2004

- Chronic Hepatitis (Typ C) inflammatory activity: portal grade 3, lobular grade 2, Fibrosis grade 4 according Ludwig, minimale Steatose (5%)
- Metavir Score: A=2, F=4.

KE, weibl. Geb. 1956, Biologin

- Was nun?
- 2004?
- 2014?

KE, female. born: 1956, biologist

- **5/2004 Peginterferon alfa 2a+ Ribavirin**
- **PCR baseline 641.000 IU/ml**
- **Week 4: 174.000 IU/ml**
- **Week 8: 149.000 IU/ml**
- **Week 12: 75.200 IU/ml**
- **Treatment terminated**

KE, female. born: 1956, biologist

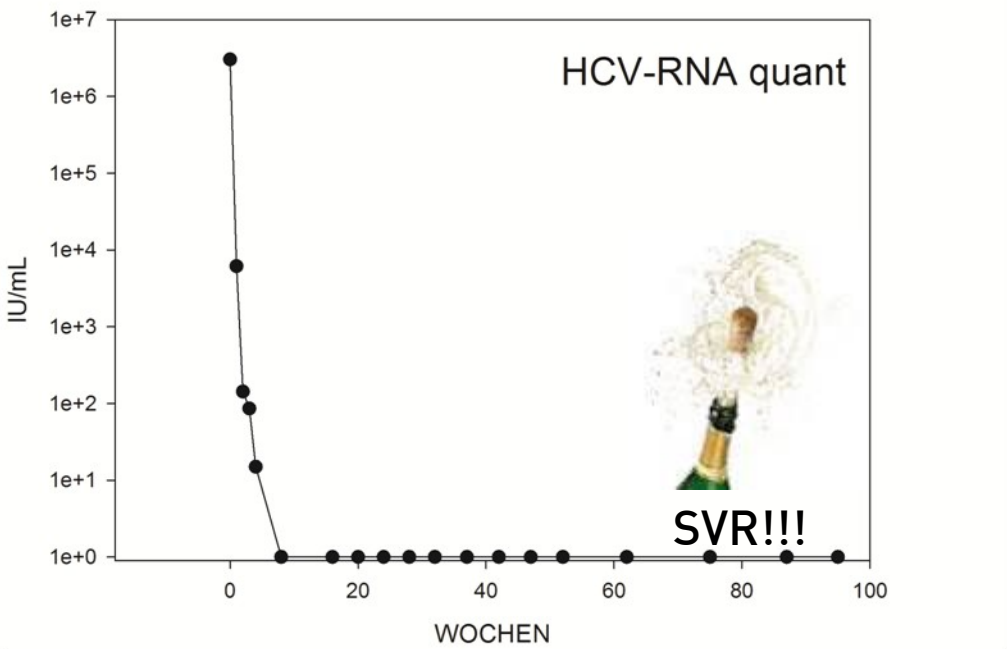
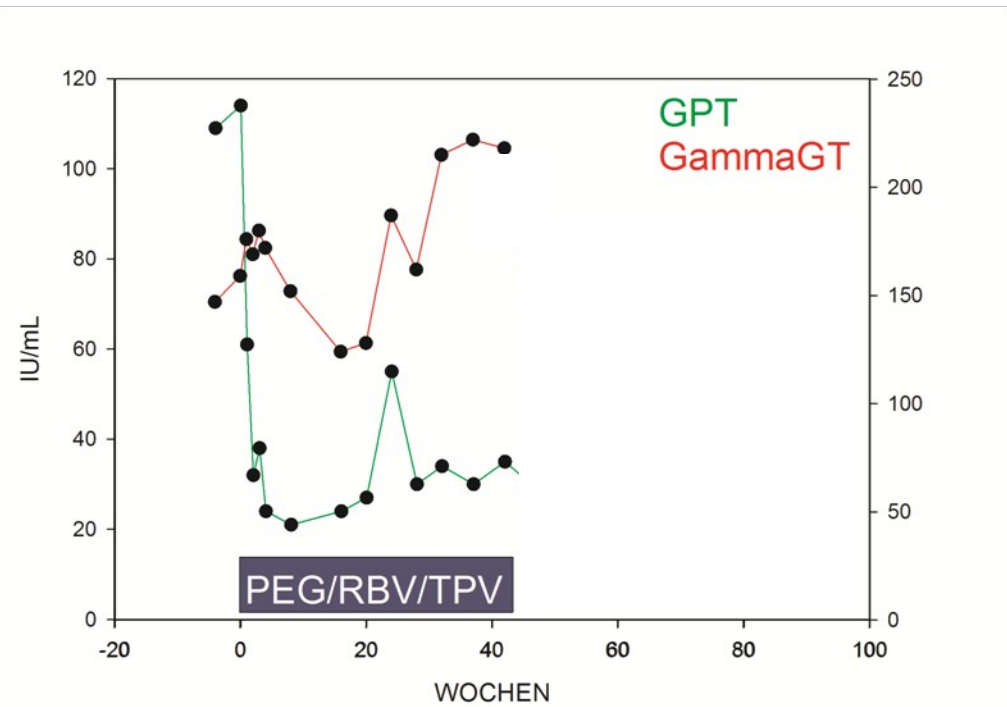
- on Ursodesoxycholic acid stable low ALT
- 2007, general tiredness, Spider naevi, Hepatosplenomegaly,
- 2009 dry eyest – ophtalmologist: Sicca Syndrome
- 2009 joint pains
- 8/2009 oral Lichen ruber planus, eating very painful, Local therapy with tacrolimus

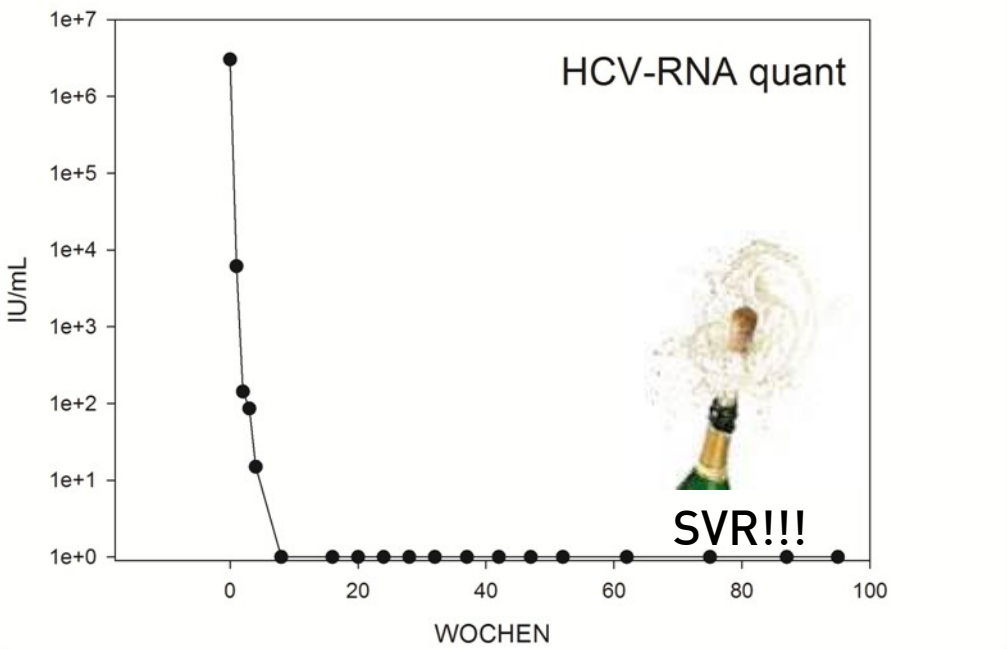
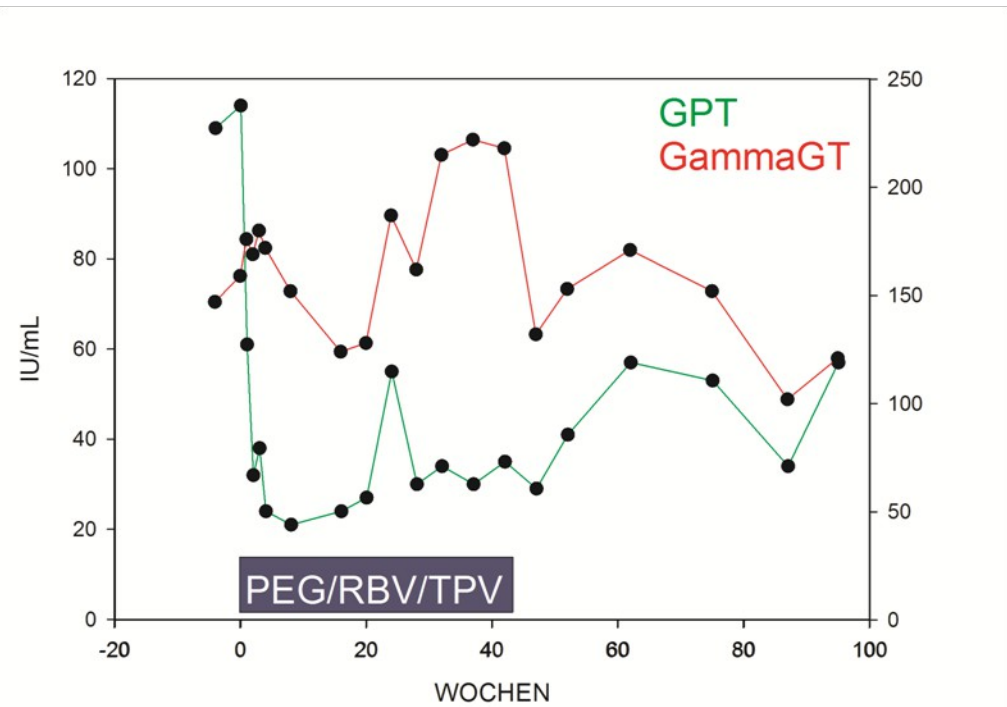
KE, female. born: 1956, biologist

- **What to do now?**
- **2012?**
- **2015?**

KE, female. born: 1956, biologist

- **9/2012 treatment with Peginterferon alfa2a+Ribavirin+Telaprevir**
- **Tolerates treatment very poorly, needs several blood transfusions (despite of lowering the dose of ribavirin)**
- **Stops treatment after week 42**





**KE, female. born: 1956,
biologist**

- **Steroids (given for 5 weeks) ineffective**
- **Patient feels well, no complaints**

KE, female, born:1956, biologist

- What do do now?